



Phytoconstituents, Hepatoprotective, and Antioxidant Activities of *Euphorbia Cooperi* N. E. Br.



Shaimaa R. Ahmed^{a,b*}, Moshera M. El-Sherei^b, Riham S. El-Dine^b, Sayed A. El-Toumy^c

^aDepartment of Pharmacognosy, College of Pharmacy, Al-Jouf University, Sakaka, Saudi Arabia

^bDepartment of Pharmacognosy, Faculty of Pharmacy, Cairo University, Cairo

^cChemistry of Tannins Department, National Research Centre, Giza, Egypt.

EXPLORATION of novel and effective therapies against liver damage with antioxidant activity is a point worth studying. The present study was aimed to evaluate the hepatoprotective and antioxidant activities of *Euphorbia cooperi* N. E. Br. aerial parts in paracetamol-induced hepatotoxicity mice and to isolate the bioactive constituents. Our findings suggest potential antioxidant and hepatoprotective activity of the n-butanol fraction of the plant, as it significantly ($P < 0.05$) prevented the increased serum marker enzymes aspartate aminotransferase and alanine aminotransferase and bilirubin levels, decreased hepatic malondialdehyde, and recovered glutathione levels. Chromatographic separation of n-butanol fraction led to isolation of seven compounds, namely, gallic acid, brevifolin carboxylic acid, kaempferol-3-O- β -D-rutinoside, corilagin, 3, 3'-dimethoxy ellagic acid, 3, 4, 4'-trimethoxy ellagic acid, and ellagic acid. The structure of isolated compounds was elucidated by physical and spectroscopic analysis and by comparison with the literature data. These compounds are isolated for the first time from *E. cooperi* N. E. Br.

Keywords: Antioxidant, Corilagin, *Euphorbia cooperi*, Hepatoprotective

Introduction

Liver is the most important and central detoxifying organ in the body. Liver injury caused by hepatotoxic agents has serious implications [1]. Reactive oxygen species production by most of the hepatotoxins is a major causative factor for lipid peroxidation and other oxidative damages, which harm liver cells [2]. In this context, it was realized that antioxidant activity or inhibition of generation of free radicals may play a crucial role in providing protection against hepatic damage. Therefore, exploring novel and effective therapies against liver damage with antioxidant activity became a point worth studying.

Genus Euphorbia (Spurge family) is the largest in the family; it includes about 2000 species, and an important proportion, mostly those from Africa and Madagascar, are succulents [3].

Euphorbia cooperi N. E. Br. is native to Eastern South Africa, South Zimbabwe, Mozambique, and Zambia. It was planted as an ornamental tree in succulent gardens or rock gardens in South Africa and the United States [4]. The plant is a succulent spiny tree, up to 5m in length. Branches are constricted into segments, inverted cordate in outline, four to six angled. Spines are in pairs and long, gray, with blackish tips. The spines form a spiky margin along each ridge on the branches. The inflorescences consist of three cymes that are vertically arranged each with three cyathia and yellowish in color. Fruits are triangular, trilobed capsules green in color that change to purple when ripe [5].

Members of the genus *Euphorbia* are well recognized by their rich content in secondary metabolites and pharmacological value [6]. Several *Euphorbia* species have been proved to

*Corresponding author, email: shaim2aarashad@yahoo.com

Received 14/12/2019; Accepted 26/12/2019

DOI: 10.21608/ejchem.2019.20992.2252

©2019 National Information and Documentation Center (NIDOC)

have antioxidant and hepatoprotective activities [2,7–15]. However, no data were found concerning these activities for *E. cooperi* N. E. Br. Herein, our attention was focused on the investigation of the hepatoprotective and antioxidant potentials of *E. cooperi* N. E. Br. to clarify the most active extracts, with the aim of isolation and characterization of bioactive principles exhibiting both activities to appraise the plant potential use as natural antioxidant and hepatoprotective remedies. To the best of our knowledge, this is the first study dealing with the antioxidant and hepatoprotective activity of *E. cooperi* N. E. Br.

Materials and Methods

Plant material

Samples of *E. cooperi* N. E. Br. aerial parts were collected in March 2017 from Ahmed Alaa botanical garden, Toukh, Qalubia, Egypt. The plant was kindly identified by Dr Mohamed El-Gebaly (Senior Botanist). A voucher specimen of the plant was deposited at the Herbarium of the Pharmacognosy Department, Faculty of Pharmacy, Cairo University, Egypt (PG 4-3-2017).

Extraction of the plant

Fresh aerial parts (25kg) of *E. cooperi* N. E. Br. after removal of latex were extracted with 70% methanol (4×4 L) at room temperature till exhaustion and then concentrated under reduced pressure to give a viscous gummy residue (200g). A portion of this residue (150g) was suspended in distilled water (500ml) and partitioned with chloroform (4×200ml) and then n-butanol (6×200ml), successively. The chloroform and n-butanol fractions were concentrated under reduced pressure to yield 40g and 50g of fraction residues, respectively.

Chemicals and reagents

Paracetamol (paramol) used to induce hepatic damage was obtained from Misr Company (Egypt). Silymarin used as a reference hepatoprotective drug was supplied by Sigma-Aldrich Chemicals Co. (St Louis, Missouri, USA). Kits used for biochemical analysis were purchased from Biodiagnostics (Giza, Egypt), for measurement of aspartate aminotransferase (AST), alanine aminotransferase (ALT), alkaline phosphatase (ALP), bilirubin, malondialdehyde (MDA), and glutathione (GSH) levels.

General Experimental Procedures

Sephadex LH-20 ((Pharmacia, USA) was used for column chromatography. Whatman No. 1 and 3MM filter paper (46×57cm) (Kent, England) was used for paper chromatography (PC). PC plates were visualized under ultraviolet lamp (at λ_{max} 365nm) before and after exposure to NH_3 vapors and spraying with $AlCl_3$ and $FeCl_3$ [16]. All solvents used were of analytical grades and purchased from El-Gomhouria Co. (Cairo, Egypt). Solvent systems A (15% acetic in water) and B [butanol–acetic acid–water (4:1:5v/v/v)] upper phase were used. Ultraviolet spectra of isolated compounds were determined in methanol and after using different shift reagents [17]. Melting points were determined using Electrothermal 9100 (UK) (uncorrected). 1H and ^{13}C nuclear magnetic resonance (NMR) spectra were recorded on Bruker High Performance Digital FT-NMR spectrophotometer (Avance III HD): 1HNMR (400MHz) and $^{13}CNMR$ (100MHz) (Bremen, Germany), which was performed at Faculty of Pharmacy, Cairo University, Egypt, using DMSO as a solvent.

Assessment of hepatoprotective and antioxidant activities

Acute toxicity

Male albino mice of Sprague–Dawley strain (25–30g) obtained from the animal house colony, National Research Centre, Giza, Egypt, were used. The LD_{50} of the methanolic extract of *E. cooperi* N. E. Br. was estimated according to Karber's procedure [18].

Experimental animal

Male albino rats of Sprague–Dawley strain weighing 130–150g were obtained from the animal house colony, National Research Centre, Giza, Egypt. Experimental animals were housed under conventional laboratory conditions throughout the period of experimentation and fed standard laboratory diet composed of vitamin mixture (1%), mineral mixture (4%), corn oil (10%), sucrose (20%), cellulose (0.2%), casein 95% pure (10.5%), and starch (54.3%) provided with water ad libitum. They were acclimatized to the laboratory conditions for at least 1 week before the experiment. All experiments involving animals were conducted according to the ethical policies and procedures approved by the ethics committee of National Research Centre.

In-vivo hepatoprotective and antioxidant study

Liver damage was induced in rats by administration of paracetamol [19]. Drugs were administered as a protective course for 14 days. Measurements were carried out after 24 hr of liver damage. Animals were divided into five groups, with six rats in each, as follows: group 1 (control group) rats received 1% tween 80 for 14 days. Group 2 (liver damaged control) rats were administered paracetamol (600mg/kg; orally). Group 3 (standard group) rats were pretreated with silymarin (50mg/kg) for 14 days before induction of liver damage with paracetamol. Groups 4–6 rats were pretreated with methanolic extract of *E. cooperi* N. E. Br. (380mg/kg), chloroform fraction (100mg/kg), and n-butanol fraction (100mg/kg) for 14 days before induction of liver damage with paracetamol. At the end of the experimental period, the animals were killed by decapitation. Blood samples (3ml) were collected in dry centrifuge tubes and left to clot at room temperature. Samples were centrifuged at 1500rpm for 10min; the clear supernatant was separated for estimation of serum parameters.

Biochemical analysis

Estimation of serum enzyme markers included ALT, AST [20], and serum ALP [21], as well as serum total bilirubin [22]. A portion of the liver was homogenized in 1.15% KCl to prepare 10% homogenate, for hepatic MDA determination [23]. Another portion of the liver was homogenized in 6% metaphosphoric acid, using Potter-Elvehjem Teflon glass homogenizer and centrifuged at 3000rpm for 15min at 4°C. The supernatant was used for the estimation of reduced liver GSH [24].

Histopathological study

Autopsy samples were taken from the liver of rats in different groups and fixed in 10% formalin for 24hr. Washing was done in tap water, and then serial dilutions of alcohol were used for dehydration. Specimens were cleared in xylene and embedded in paraffin at 56°C in hot air oven for 24hr. Paraffin bees wax tissue blocks were prepared for sectioning at 4- μ m thickness by sledge microtome. The obtained tissue sections were collected on glass slides, deparaffinized, and stained by hematoxylin and eosin stain for examination through the light electric microscope [25]. Photomicrographs obtained are presented in Fig. 1 and 2.

Statistical analysis

The results were expressed as mean \pm SEM. Statistical analysis was carried out by one-way analysis of variance followed by Tukey–Kramer’s

multiple comparison. P value less than or equal to 0.05 was considered significant.

Isolation and purification of constituents

The n-butanol fraction of *E. cooperi* (40g) displayed significant hepatoprotective and antioxidant activities. The fraction was subjected to chromatographic separation for characterization of active constituents by using polyamide column chromatography (6.5 \times 65cm). Gradient elution was carried out using water/methanol mixtures (0–100% methanol). Fractions of 500ml were collected, evaporated under reduced pressure, and monitored by PC using the solvent systems A and B. Similar fractions were pooled together, yielding four collective fractions, which were subjected to further purification for isolation of their components.

Fraction A (3.5g), eluted with 40% methanol, was subjected to preparative PC (3MM Whatman filter paper) using 15% acetic acid in water and then further purified by sephadex LH-20, and eluted with methanol to give compound 1 (53mg).

Fraction B (10g), eluted with 40% methanol, was subjected to sephadex LH-20 column, eluted with 20–40% methanol, to yield three subfractions. Subfraction 1B (250mg) was subjected to sephadex LH-20 column, eluted with n-butanol, saturated with water (upper layer), and then then subjected to sephadex LH-20 column eluted by 50% methanol to afford compound 2 (40mg). Subfraction 2B (400mg) was subjected to sephadex LH-20 column, eluted with 20% methanol, yielding compound 3 (76mg). Subfraction 3B (1.4g) was subjected to sephadex LH-20 column, eluted with 20% methanol, to give compound 4 (61mg).

Fraction C (5.4g), eluted with 60–80% methanol, was chromatographed using sephadex LH-20 column, eluted by 20% methanol. Subfraction 1C (2g) was subjected to sephadex LH-20 column eluted with n-butanol saturated with water (upper layer) then applied on sephadex LH-20 column and eluted by 50% methanol, and finally, was subjected to preparative PC (3MM Whatman filter paper) using 15% acetic acid/water as eluent. The chromatogram showed two major bands which were cut and eluted with methanol. Each eluted band was further purified on sephadex LH-20 column chromatography using 20% methanol as solvent to give compound 5 (30mg) and compound 6 (15mg).

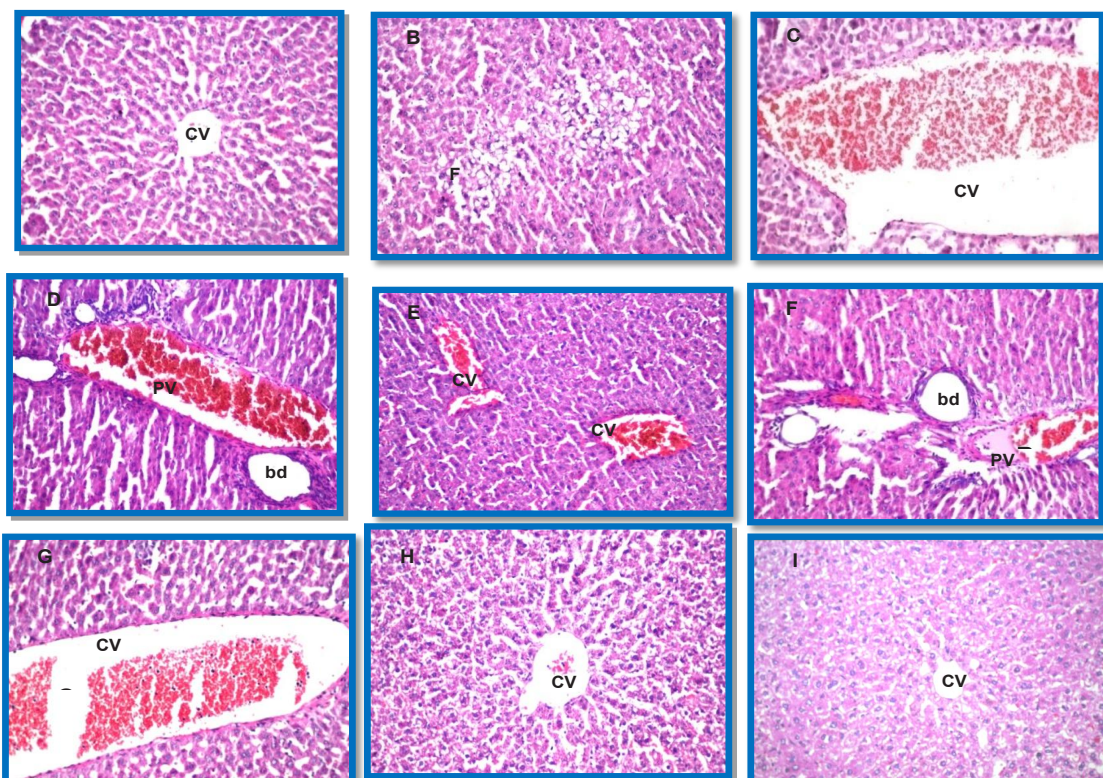


Fig. 1. Photomicrograph of liver sections of normal rats (a), paracetamol treated rats (b, c, d), methanolic extract (e) and chloroform fraction (f & g), n-butanol fraction (h) of aerial parts of *E. cooperi* pretreated rats and Silymarin (I) pretreated rats.

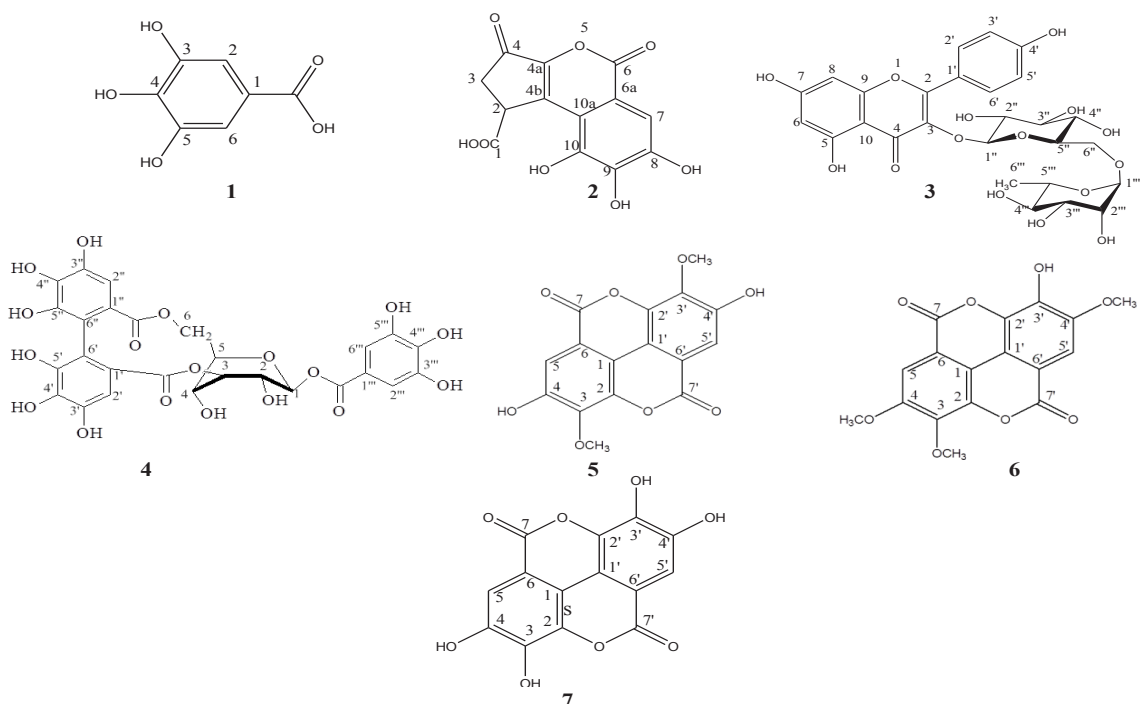


Fig. 2. Structures of isolated compounds from *E. cooperi* N.E.Br.

Fraction D (4.6g), eluted with methanol, was purified on a sephadex LH-20 column using methanol for elution followed by sephadex LH-20 column eluted with 90% methanol, yielding compound 7 (70mg).

Identification of isolated compounds

Gallic acid (1) showed the following characteristics: white powder (53mg); molecular formula: C₇H₆O₅; mp: 255–258°C; ¹H NMR (400MHz, DMSO) δH: 9.17 (brs, three OH at position 3, 4, and 5) and 6.92 (2H, s, H-2, H-6); and ¹³C NMR (100MHz, DMSO) δc: 167.96 (C=O), 145.85 (C-3, C-5), 138.44 (C-4), 120.91 (C-1), and 109.20 (C-2, C-6) [26,27].

Brevifolin carboxylic acid (2) showed the following characteristics: yellow amorphous powder (40mg); mp: 200–201°C; ¹H NMR (400MHz, DMSO) δH: 7.17 (1H, s, H-7), 2.93 (2H, d, J=7.4Hz, H-3), and 4.39 (1H, d, J=6.6Hz, H-2); and ¹³C NMR (100MHz, DMSO) δc: 194.35 (C-4), 175.13 (C-1), 161.16 (C-6), 149.56 (C-4a), 146.01 (C-10), 143.58 (C-8), 140.02 (C-10a), 139.80 (C-9), 115.01 (C-4b), 113.36 (C-6a), 107.71 (C-7), 40.99 (C-2), and 37.32 (C-3) [28].

Kaempferol-3-O-β-D-rutinoside (3) showed the following characteristics: yellow amorphous powder (76mg); molecular formula: C₂₇H₃₀O₁₅; mp: 220–222°C; ¹H NMR (400MHz, DMSO) δH: 7.99 (2H, d, J=8.7Hz, H-2', 6'), 6.88 (2H, d, J=8.7Hz, H-3', H-5'), 6.42 (1H, d, J=1.6Hz, H-8), 6.21 (1H, d, J=1.6Hz, H-6), 5.32 (1H, d, J=7.4Hz, H-1' for glucose), 4.38 (1H, s, H-1'' for rhamnose), and 0.99 (3H, d, J=6.12Hz, H-6'' methyl of rhamnose); and ¹³C NMR (100MHz, DMSO) δc: 177.84 (C-4), 164.63 (C-7), 161.66 (C-5), 160.35 (C-4'), 157.31 (C-9), 156.96 (C-2), 133.68 (C-3), 131.34 (C-2', 6'), 121.26 (C-1'), 115.56 (C-3', 5'), 104.44 (C-10), 101.80 (C-1''), 101.22 (C-1'''), 99.20 (C-6), 94.21 (C-8), 76.82 (C-3'), 76.20 (C-5'), 74.63 (C-2'), 72.28 (C-4''), 71.06 (C-4'), 70.81 (C-2''), 70.38 (C-3''), 68.99 (C-5''), 68.71 (C-6'), and 18.18 (C-6'') [29,30].

Corilagin (4) showed the following characteristics: pale brown amorphous powder (61mg), molecular formula: C₂₇H₂₂O₁₈; mp: 220°C; ¹H NMR (400MHz, DMSO) δH: glucose moiety: 6.23 (1H, d, J=7.08Hz, H-1), 4.62 (1H, brs, H-3), 4.38 (1H, t, J=8.2Hz, H-5), 4.26 (1H, d, J= 11.8Hz, H-6), 4.24 (1H, s, H-4), 3.98 (1H, m, H-6'), and 3.89 (1H, d, J=7.16Hz, H-2), and galloyl moiety: 7.04 (2H, s, H-2'', 6''); and ¹³C

NMR (100MHz, DMSO) δc: HHDP moiety: 6.58 (1H, s, H-2') and 6.51 (1H, s, H-2''), glucose moiety: 92.53 (C-1), 71.99 (C-2), 77.74 (C-3), 64.42 (C-4), 76.41 (C-5), and 62.55 (C-6), galloyl moiety: 119.18 (C-1'''), 109.48 (C-2''', 6'''), 146.06 (C-3''', 5'''), 139.47 (C-4'''), and 165.29 (C=O), and HHDP moiety: 123.56, 124.37 (C1', 1'), 106.39, 107.30 (C-2', 2''), 144.42, 144.74 (C-3', 3''), 145.30, 145.39 (C-5', 5''), 135.91, 136.04 (C4', 4''), 116.03, 116.30 (C-6', 6''), and 167.22, 167.57 (C=O) [31].

3, 3'-dimethoxy ellagic acid (5) showed the following characteristics: yellow amorphous powder (30mg); molecular formula: C₁₆H₁₀O₈; ¹H NMR (400MHz, DMSO) δH: 7.33 (2H, s, H-5, 5') and 3.99 (6H, s, OCH₃ at 3,3'); and ¹³C NMR (100MHz, DMSO) δc: 60.19 (3, 3'-OCH₃), 109.33 (C-6, 6'), 111.66 (C-5,5'), 112.96 (C-1,1'), 141.20 (C-2, 2'), 141.59 (C-3, 3'), 152.51 (C-4, 4'), and 159.81 (C-7, 7') [32].

3, 4, 4'-trimethoxy ellagic acid (6) showed the following characteristics: yellow amorphous powder (15mg); ¹H NMR (400MHz, DMSO) δH: 7.53 (1H, s, H-5), 7.25 (1H, s, H-5'), 4.02 (6H, s, OCH₃-4, 4'), and 3.96 (3H, s, OCH₃-3); and ¹³C NMR (100MHz, DMSO) δc: 61.64 (3-OCH₃), 57.01 (4-OCH₃), and 56.49 (4'-OCH₃) [33].

Ellagic acid (7) showed the following characteristics: white amorphous powder (70mg); ¹H NMR (400MHz, DMSO) δH: 7.46 (2H, s, H-5, 5'); and ¹³C NMR (100MHz, DMSO) δc: 108.04 (C-6,6'), 110.67 (C-5,5'), 112.39 (C-1,1'), 136.84 (C-2, 2'), 140.12 (C-3,3'), 148.59 (C-4,4'), and 159.61 (C-7,7') [31].

Results and Discussion

Methanolic extract of *E. cooperi* N. E. Br. was safe and nontoxic (LD₅₀=3.8g/kg body weight) [34]. The results of hepatoprotective and antioxidant studies (Tables 1 and 2) revealed that administration of paracetamol at a dose of 600mg/kg significantly (P<0.05) increased serum ALT (610.6%), AST (292.5%), serum bilirubin (55.5%), and hepatic MDA (69.8%) and depleted the hepatic GSH (56.0%) when compared with control rats; however, serum ALP levels were not significantly changed. Pretreatment with the methanolic extract of the aerial parts of *E. cooperi* N. E. Br. at a dose of 380mg/kg significantly (P<0.05) showed an inhibition in the paracetamol-induced elevated levels of serum ALT (17.3%), AST (54.1%), and total bilirubin

(28.6%). Likewise, it significantly decreased the formation of lipid peroxidation product MDA (37.9%) and restored the level of hepatic GSH (78.1%). However, pretreatment with the chloroform fraction of the aerial parts at a dose of 100mg/kg showed no significant effect on the paracetamol-induced elevated levels of serum ALT, AST, and total bilirubin (4.2, 11.7, and 0%, respectively) as well as the depleted GSH. Only, it is significantly decreased the formation of MDA (25.6%). Pretreatment with the n-butanol fraction of the aerial parts at a dose of 100mg/kg showed significant inhibition on the paracetamol-induced elevated levels of serum ALT, AST, and total bilirubin (55.8, 90.5, and 35.7%, respectively). It is significantly decreased the formation of hepatic MDA and restored the level of GSH (42.5 and 104.1%, respectively). The highest activity was observed by the n-butanol fraction followed by the methanol extract, whereas the chloroform fraction showed the least activity, all compared with the standard drug, silymarin.

For screening of hepatoprotective agents, paracetamol-induced hepatotoxicity in experimental animals has been used as a reliable method [35]. The ALT, AST, and ALP activity and serum bilirubin level are the most common biochemical markers to evaluate liver injury. Administration of paracetamol caused a significant elevation of AST, ALT, ALP, and bilirubin level owing to the damaged structural integrity of liver [36]. The co-administration of the methanolic extract of the aerial parts as well as its n-butanol fraction prevented the increased serum marker enzymes AST and ALT and bilirubin levels. This is in agreement with commonly accepted view that serum levels of ALT and AST return to normal with the healing of hepatic parenchyma and regeneration of hepatocytes [37]. On the contrary, it has been hypothesized that one of principal causes of paracetamol-induced liver injury is lipid peroxidation by free radical derivatives [35]. MDA is one of the main toxic end products of lipid peroxidation; hence, it is widely used as a reliable index of lipid peroxidation [38]. Reduced GSH is one of the most abundant biological antioxidants present in the liver and constitutes the first line of defense against free radicals in liver [39]. Therefore, GSH is a reasonable marker for the evaluation of oxidative stress, and maintaining its level is very important to prevent lipid peroxidation [40]. In the current study, increased oxidative stress

was observed in paracetamol-treated rats, as evidenced by the remarkable increase in hepatic MDA levels with significant depletion of hepatic GSH. Pretreatment with the methanolic extract of the aerial parts of *E. cooperi* N. E. Br. and its n-butanol fraction significantly decreased hepatic MDA and recovered GSH levels.

Histopathological study of the photomicrographs of liver from the normal group showed a normal hepatic architecture with distinct hepatic cells, sinusoidal spaces, and central vein (Fig. 1a). No evidence of degeneration or necrosis or inflammatory reaction could be observed. In contrast, liver sections of paracetamol-treated group (Fig. 1b–d) showed marked histopathological alterations characterized by fatty degeneration in hepatocytes, severe dilatation, and congestion of the central and portal veins as well as dilatation of bile duct with periductal inflammatory cell infiltration. Pretreatment with the methanolic extract of the aerial parts of *E. cooperi* N. E. Br. (Fig. 1e) restored the liver structure to nearly normal, as seen by marked regression of the histopathological alteration recorded in the paracetamol-intoxicated group with only mild dilatation in central vein. However, in the group pretreated with chloroform fraction (Fig. 1f, g), the histopathological changes recorded in paracetamol-intoxicated group remained, with marked dilatation and congestion in the portal and central vein as well as dilatation of bile duct. In contrast, photomicrographs of liver pretreated with n-butanol fraction (Fig. 1h) resembled to a great extent that of normal group showing marked improvement and reversion of the histopathological lesions demonstrated in the paracetamol-intoxicated group, which was comparable to the silymarin pretreated group (Fig. 1i).

The evident control on ALT, AST, and total bilirubin parameters, exerted by methanolic extract of aerial parts of *E. cooperi* N. E. Br. and its n-butanol fraction reflects an improvement in the secretory mechanism of the intoxicated hepatocytes. In the same context, the biochemical findings obviously correlate with the results of histopathological examination of the isolated liver tissues. As a matter of fact, the histological features of hepatocellular damage manifested by degeneration (fatty change) in hepatocytes, severe dilatation, and congestion of the central and portal veins as well as dilatation of bile duct with periductal inflammatory cells infiltration,

were markedly ameliorated on pretreatment with methanolic extract of aerial parts of *E. cooperi* N. E. Br. and its n-butanol fraction.

The chromatographic separation of the n-butanol fraction led to isolation of seven compounds. These compounds were identified as gallic acid, brevifolin carboxylic acid, kaempferol-3-O- β -D-rutinoside, corilagin, 3, 3'-dimethoxy ellagic acid, 3, 4, 4'-trimethoxy ellagic acid, and ellagic acid based on physical and spectroscopic analysis and by comparison with the literature data. All the seven compounds are known molecules; however, they are reported in *E. cooperi* as the major constituents for the first time.

The n-butanol fraction of the aerial parts showed significant hepatoprotective and high antioxidant activities owing to the presence of flavonoids (kaempferol-3-O- β -rutinoside), phenolic acids (gallic acid), and tannins

(brevifolin carboxylic acid, corilagin, dimethoxy and trimethoxy ellagic acid, and ellagic acid).

This is in agreement with literature, which reported that flavonoids from Euphorbiaceae are well documented for their anti-tumor, hepatoprotective, and antioxidant activities [41]. Ellagic acid is known to possess hepatoprotective and antioxidant properties [13]; moreover, tannins are strong antioxidant [42].

Conclusion

E. cooperi n-butanol fraction showed promising hepatoprotective effect based on antioxidant potential. Chromatographic separation of n-butanol fraction afforded seven compounds: gallic acid, brevifolin carboxylic acid, kaempferol-3-O- β -D-rutinoside, corilagin, 3, 3'-dimethoxy ellagic acid, 3, 4, 4'-trimethoxy ellagic acid, and ellagic acid. This study is considered as the first report for the isolation of these compounds from *E. cooperi*.

TABLE 1. Effect of treatment with the methanolic extract, chloroform and n-butanol fractions of *Euphorbia cooperi* on serum alanine aminotransferase, aspartate aminotransferase, alkaline phosphatase, and bilirubin level in paracetamol-induced hepatotoxicity in rats

Groups	Dose (mg/kg b.wt.)	ALT (U/L)		AST (U/L)		ALP (U/L)		Bilirubin (mg/dl)		
		M \pm S. E.	% change	M \pm S.E.	% change	M \pm S.E.	% change	M \pm S.E.	% change	
Normal control		35.04 \pm 3.61	-	219.50 \pm 10.10	-	120.35 \pm 1.69		0.09* \pm 0.01	-	
Liver damaged group		249.00* \pm 9.76	+ 610.6	861.50* \pm 5.40	+ 292.5	129.41* \pm 6.77	+7.5	0.14* \pm 0.01	+55.5	
Paracetamol (600 mg/kg)	Methanolic extract	380								
			205.90* ^a \pm 8.9	-17.3	395.50* ^a \pm 11.25	-54.1	138.67* \pm 9.61	+7.1	0.10* ^a \pm 0.003	-28.6
	Chloroform fraction	100								
			238.44* \pm 8.3	-4.2	761.00* \pm 3.4	-11.7	159.02* \pm 2.15	+22.8	0.14* \pm 0.01	0
	n-butanol fraction	100								
			144.90* ^a \pm 11.9	-55.8	82.24* ^a \pm 2.34	-90.5	134.10* ^a \pm 9.6	+3.6	0.09* ^a \pm 0.005	-35.7

Data were expressed as mean \pm SE (n=6). *Significantly different from normal control (Saline) at P<0.05, aSignificantly different from liver damaged group at P<0.05,

TABLE 2. Effect of treatment with the methanolic extract, chloroform and n-butanol fractions of *Euphorbia cooperi* on hepatic MDA and GSH in paracetamol-induced hepatotoxicity in rats

	Groups	Dose (mg/ kg b.wt.)	Hepatic MDA (mmol/g wet tissue)		Hepatic GSH (mmol/g wet tissue)	
			% change	M ± S. E.	% change	
			M ± S. E.			
Paracetamol (600 mg/kg)	Normal control		4.63 ± 0.17	-	1.66 ± 0.05	-
	Liver damaged group		7.86* ± 0.82	+69.8	0.73* ± 0.01	-56.0
	Methanolic extract	380	4.88* ± 0.76	-37.9	1.30* ± 0.16	+78.1
	Chloroform fraction	100	5.85* ± 0.61	-25.6	0.57* ± 0.04	-21.9
	n-butanol fraction	100	4.52* ± 0.61	-42.5	1.49* ± 0.15	+104.1
	Silymarin	50	4.90* ± 1.80	-37.7	1.75* ± 0.12	+139.7

Data were expressed as mean ± SE (n=6). *Significantly different from normal control (Saline) at P<0.05, aSignificantly different from liver damaged group at P<0.05

References

- Sharma S., Chemoprotective activity of hydro-ethanolic extract of *Euphorbia nerifolia* Linn leaves against DENA-induced liver carcinogenesis in mice. *Biol Med*, **3**, 36-44 (2011)
- Jyothi T., Shankariah M., Prabhu K., Lakshminarasu S., Srinivasa G., and Ramachandra S.S., Hepatoprotective and antioxidant activity of *Euphorbia tirucalli*. *Iranian Journal of Pharmacology and Therapeutics*, **7** (1), 25-0 (2008).
- Jassbi A.R., Chemistry and biological activity of secondary metabolites in *Euphorbia* from Iran. *Phytochemistry*, **67** (18), 1977-1984 (2006)
- Coates Palgrave K., Drummond R.B., Moll E.J., and Coates Palgrave M., *Trees of southern Africa*. Cape Town: Struik Nature (2008)
- Bailey L.H., The standard cyclopedia of horticulture : a discussion for the amateur and the professional and commercial grower, of the kinds, characteristics and methods of cultivation of the species of plants grown in the regions of the United States and Canada for ornament, for fancy, for fruit and for vegetables. N. Y. Macmillan (1953).
- Fernandez-Arche A., Saenz M., Arroyo M., De la Puerta R. and Garcia M., Topical anti-inflammatory effect of tirucallol, a triterpene isolated from *Euphorbia lactea* latex. *Phytomedicine*, **17** (2), 146-148 (2010).
- Barla A., Öztürk M., Kültür Ş., and Öksüz S., Screening of antioxidant activity of three *Euphorbia* species from Turkey. *Fitoterapia*, **78** (6), 423-425 (2007).
- Battu G.R., Ethadi S.R., Priya G.V., Priya K.S., Chandrika K., Rao A.V., and Reddy S.O., Evaluation of antioxidant and anti-inflammatory activity of *Euphorbia heyneana* Spreng. *Asian Pacific Journal of Tropical Biomedicine*, **1** (2), S191-S194 (2011)
- Basma A.A., Zakaria Z., Latha L.Y., and Sasidharan S., Antioxidant activity and phytochemical screening of the methanol extracts of *Euphorbia hirta* L. *Asian Pacific Journal of Tropical Medicine*, **4** (5), 386-390 (2011).
- Ul-Haq I., Ullah N., Bibi G., Kanwal S., Ahmad M.S., and Mirza B., Antioxidant and cytotoxic activities and phytochemical analysis of *Euphorbia wallichii* root extract and its fractions. *Iranian Journal of Pharmaceutical Research: IJPR*, **11** (1), 241 (2012).
- Ouml, zlem S.A., RK, Tuuml, lay A.C., and EL□K, Antioxidant, cytotoxic and apoptotic activities of extracts from medicinal plant *Euphorbia platyphyllos* L. *Journal of Medicinal Plants Research*, **7** (19), 1293-1304 (2013).
- Singh S., Prabha T., Kavitha B., Chouhan H., and Bharti S.K., Anti-inflammatory and hepatoprotective activities of ethanolic extract of *Euphorbia thymifolia* Linn. *Pharmacologyonline*, **1**, 986-994 (2009).
- Anusuya N., Raju K., and Manian S., Hepatoprotective and toxicological assessment of an ethnomedicinal plant *Euphorbia fusiformis* Buch.-

- Ham. ex D. Don. *Journal of Ethnopharmacology*, 127 (2), 463-467 (2010)
14. Dubey S. and Mehta S., Hepatoprotective activity of *Euphorbia hirta* Linn. Plant against carbon tetrachloride-induced hepatic injury in rats. in *International Conference on Food, Biological and Medical Sciences, FBMS*. (2014)
15. Periasamy M., Pavankumar K., Gangadhar V., Jeeva T., Anandhan R., and Sengottuvelu S., Hepatoprotective and anti-oxidant activity of *Euphorbia ligularia* against carbon tetrachloride induced hepatotoxicity in Wistar rats. *Int. J. Res. Pharm. Biomed. Sci.*, **3**, 100-04 (2012).
16. Stahl E., *Thin-Layer Chromatography : A Laboratory Handbook*. New York: Springer-Verlag (1969).
17. Mabry T.J., Markham K.R., and Thomas M.B., *The Systematic Identification of Flavonoids* [by] T.J. Mabry, K.R. Markham, and M.B. Thomas. New York: Springer-Verlag (1970).
18. Karber G., Archives of Experimental Pathology and Pharmacology. 50% end-point calculation, 162, 480-483 (1931).
19. Silva V.M., Thibodeau M.S., Chen C. and Manautou J.E., Transport deficient (TR-) hyperbilirubinemic rats are resistant to acetaminophen hepatotoxicity. *Biochemical Pharmacology*, **70** (12), 1832-1839 (2005).
20. Reitman S. and Frankel S., A colorimetric method for the determination of serum glutamic oxalacetic and glutamic pyruvic transaminases. *American Journal of Clinical Pathology*, **28** (1), 56-63 (1957).
21. Belfield A. and Goldberg D., Revised assay for serum phenyl phosphatase activity using 4-amino-antipyrine. *Enzyme*, 12, 561-573 (1971).
22. Walter M. and Gerade R., Bilirubin direct/total. *Microchem. J.*, 15, 231-233 (1970).
23. Uchiyama M. and Mihara M., Determination of malonaldehyde precursor in tissues by thiobarbituric acid test. *Analytical Biochemistry*, **86** (1), 271-278 (1978).
24. Beutler E., Improved method for the determination of blood glutathione. *J. Lab. Clin. Med.*, **61**, 882-888 (1963).
25. Bancroft J., Stevens A., and Turner D., *Theory and Practice of Histological Techniques*. 4th ed Churchill Living Stone, New York Edinburgh. Madrid, Sanfrancisco (1996)
26. Anil M. and Nandini P., Simultaneous isolation and identification of phytoconstituents from *Terminalia chebula* by preparative chromatography. *Journal of Chemical and Pharmaceutical Research*, **2** (5), 97-103 (2010).
27. Constitutive Phenolics and Hepatoprotective Activity of *Eugenia supra-axillaris* Leaves. *Egyptian Journal of Chemistry*, **54** (3), 313-323 (2011).
28. N'guessan J., Bidié A., Lenta B., Weniger B., Andre P., and Guédé-Guina F., In vitro assays for bioactivity-guided isolation of antisalmonella and antioxidant compounds in *Thonningia sanguinea* flowers. *African Journal of Biotechnology*, **6** (14), (2007).
29. Orhan D.D., Ergun F., YEŞİLADA E., TSUCHIYA K., TAKAISHI Y., and KAWAZOE K., Antioxidant activity of two flavonol glycosides from *Cirsium hypoleucum* DC. through bioassay-guided fractionation. *Turkish J. Pharm. Sci.*, **4** (1), 1-14 (2007)
30. Chemical Constituents, Antischistosomal and Antioxidant Activities of the Methanolic Extract of *Azadirachta indica*. *Egyptian Journal of Chemistry*, **54** (1), 99-113 (2011)
31. Nawwar M.A., Hussein S.A., and Merfort I., NMR spectral analysis of polyphenols from *Punica granatum*. *Phytochemistry*, **36** (3), 793-798 (1994).
32. Pakulski G. and Budzianowski J., Ellagic acid derivatives and naphthoquinones of *Dionaea muscipula* from in vitro cultures. *Phytochemistry*, **41** (3), 775-778 (1996).
33. Bindra R., Satti N., and Suri O., Isolation and structures of ellagic acid derivatives from *Euphorbia acaulis*. *Phytochemistry*, **27** (7), 2313-2315 (1988).
34. Buck W.B., Osweiler G.D., and Van Gelder G.A., *Clinical and Diagnostic Veterinary Toxicology*. Dubuque, Iowa: Kendall/Hunt (1976).
35. Muthulingam M., Mohandoss P., Indra N., and Sethupathy S., Antihepatotoxic efficacy of *Indigofera tinctoria* (Linn.) on paracetamol induced liver damage in rats. *Int J. Pharm Biomed Res.*, **1** (1), 13-18 (2010).
36. Parmar S.R., Vashrambhai P.H., and Kalia K., Hepatoprotective activity of some plants extract against paracetamol induced hepatotoxicity in rats. *Egypt.J.Chem.* **62**, Special Issue (Part 2) (2019)

- J. Herbal Med. Toxicol.*, **4** (2), 101-106 (2010).
37. Wolf P.L., Biochemical diagnosis of liver disease. *Indian Journal of Clinical Biochemistry*, **14** (1), 59-90 (1999).
38. Kosugi H., Kojima T., and Kikugawa K., Thiobarbituric acid creactive substances from peroxidized lipids. *Lipids*, **24** (10), 873-881 (1989).
39. Prakash J., Gupta S., Kochupillai V., Singh N., Gupta Y., and Joshi S., Chemopreventive activity of *Withania somnifera* in experimentally induced fibrosarcoma tumours in Swiss albino mice. *Phytotherapy Research: An International Journal Devoted to Pharmacological and Toxicological Evaluation of Natural Product Derivatives*, **15** (3), 240-244 (2001).
40. Lim H.-K., Kim H.-S., Choi H.-S., Oh S., and Choi J., Hepatoprotective effects of bergenin, a major constituent of *Mallotus japonicus*, on carbon tetrachloride-intoxicated rats. *Journal of Ethnopharmacology*, **72** (3), 469-474 (2000).
41. Chaabi M., Freund-Michel V., Frossard N., Randriantsoa A., Andriantsitohaina R., and Lobstein A., Anti-proliferative effect of *Euphorbia stenoclada* in human airway smooth muscle cells in culture. *Journal of Ethnopharmacology*, **109** (1), 134-139 (2007).
42. Okuda T., Systematics and health effects of chemically distinct tannins in medicinal plants. *Phytochemistry*, **66** (17), 2012-2031 (2005).